

A Study On The Prevailing Ectoparasitological Diseases Among Cultured *Oreochromis niloticus*

Shaheen A.A*; Amany A. Abbass* and Lubna M. El-Akabwy**

*Dept. of Fish Diseases and Management, Fac. Vet. Med., Moshtohor, Zag. Univ. Benha branch.

**Dept. of Parasitology, Fac. Vet. Med., Moshtohor, Zag. Univ. Benha branch.

ABSTRACT

In the present study Ichthyobodosis and White spot disease were recorded in cultured *O. niloticus*. The prevalence of infection among the examined fish was 22.86 and 33.57% respectively. Both diseases were recorded at higher incidence during the autumn followed by winter while, the spring season showed moderate incidence for both diseases. During the summer season cases of ichthyobodosis and white spot disease were not observed. The rate of infestation among fry and fingerlings was higher than those of adults in both ichthyobodosis and white spot disease. The signs and lesions, observed on naturally infected fish, were recorded. In addition, free-swimming parasitic stages as well as encysted forms of the identified protozoa were recognized. The morphological description of the isolated protozoans was also discussed.

INTRODUCTION

Different protozoal diseases were found to affect fish causing considerable damage. Ichthyobodosis caused by Bodonid flagellate *Ichthyobodo necator* is considered primarily as a freshwater fish ectoparasite with a wide host range (1, 2). Meanwhile, *I. necator* isolated from freshwater fish was survived and multiplied in seawater (3). If the infected fish transferred from freshwater to seawater the parasite could be collected from the sea (4). Young fish are more susceptible than adult one and heavy infection results in high mortalities (2, 5,6). At higher temperatures the generation doubling time can be as little as a few hours. Moreover, higher infestation rate among cultured fish was recorded in warm water ponds as well as during cold season in some countries (7).

White spot disease (Ich) caused by holotrich ciliate *Ichthyophthirius multifiliis* is perhaps the major ectoparasitic protozoan of freshwater fishes in tropical and sub-arctic zones (7, 8). The disease firstly originated in Asia (9) then spread to Europe causing a major problem in fish culture (10) and become a worldwide distribution as a result of fish transportation (11). The disease outbreak was reported in an intensive cultured fish in South Africa (12). In warm water fish the outbreak usually recorded during the period between

fall and spring, as the parasite prefers a relatively lower temperature (13). The parasite usually inhabiting skin and gills resulted in morbidity and mortality of infected fishes (14, 15-17). In addition to the usual sites the invasion, the parasite was found within the peritoneal cavity of some experimentally infected fish (18).

This study was planned to investigate some prevailing protozoal diseases in cultured *O. niloticus*, as well as the influence of seasonal variation and age on ectoparasitic infection.

MATERIALS AND METHODS

Fish

A total of 280 *Oreochromis niloticus*, were examined, 70 fish at every season. Fry, fingerlings and adults were included (fish were examined according to the available size at each season). Fish samples were collected randomly from Abbassa Fish Hatchery during the different seasons (2000). The obtained fish were transported alive with sufficient amount of their natural water in polyethylene bags under all accurate methods of transportation (19). The fish were kept in a well-prepared aquaria at the Lab of Fish Diseases and Management Faculty of Veterinary Medicine, Moshtohor, for further examinations.

Clinical examination

The collected fish were examined for clinical signs gross lesions as described by Amlacker (20).

Parasitological examination

Fresh mount preparations were taken from the gills, skin and fins of the collected fish and examined microscopically (21). The slides were then fixed with methyl alcohol and stained with Giemsa stain according to Lucky (22). Identification of the obtained protozoa was carried out (23- 26). Measurements of the recovered protozoa were carried out to determine their average size.

RESULTS AND DISCUSSION

Out of 280 examined *O. niloticus*, a total of 94 fish were infected with parasitic protozoans in a rate of 33.57%. The recovered protozoa were identified as *Ichthyoboda necator* and *Ichthyophthirius multifiliis*. Both protozoa were recorded as a mixed infection in

22.86% of the total infected fish. These results are similar to those recorded by Beck et al. (27) who found a double infection by *I. necator* and *Cryptocaryon sp.* in spadefish. As shown in (Table 1, Fig. 1) the prevalence of infection with ichthyobodosis among the examined fish was 22.86%. In the same respect Urawa and Kusakari (3) found that 40% of the examined salmon fry were infected with *I. necator* and Urawa et al. (28) recorded that the prevalence of infection among juvenile flounder in hatchery was 40%. While the prevalence of infection with *I. multifiliis* was 33.57% among the examined fish. These observations were higher than that reported by Wahli and Meier (29) and Lower than that recorded by Moustafa and Easa (14) and Ali (17).

Concerning the seasonal variation both protozoa were mainly recorded during autumn and winter (Table 1, Fig. 1). The obtained results were nearly similar with those reported by Urawa and Kusakari (3) and Urawa et al. (28).

Table (1): Seasonal prevalence of Ichthyobodosis and White spot disease in *O. niloticus*.

Season	No of exam. Fish	No. of infested fish	% of infestation	Ichthyobodosis		White spot disease		Mixed infestation	
				No of infested fish	% of infestation	No of infested fish	% of infestation	No of infested fish	% of infestation
Spring	70	27	38.57	17	24.29	27	38.57	17	24.29
Summer	70	-	-	-	-	-	-	-	-
Autumn	70	37	52.85	25	35.71	37	52.85	25	35.71
Winter	70	30	42.86	22	31.43	30	42.86	22	31.43
Total	280	94	33.57	64	22.86*	94	33.57*	64	22.86

*Prevalence of infection for the total examined fish.

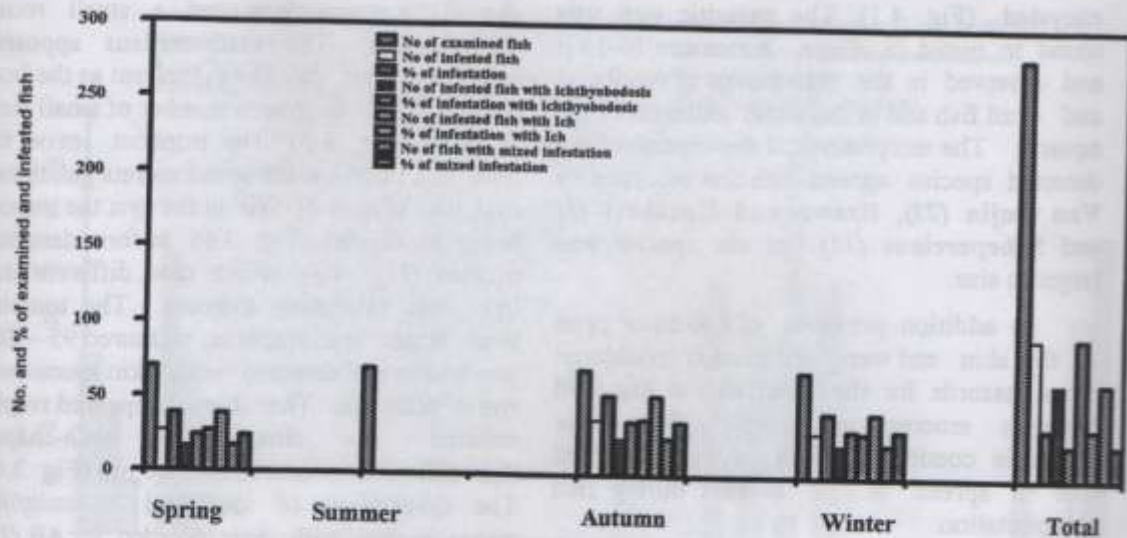


Fig. (1): Seasonal prevalence of Ichthyobodosis and White spot disease in *O. niloticus*.

As shown in (Table 2, Fig. 2) whenever, all fish stages (Fry, fingerlings, adults) were available; the rate of infestation with ichthyobodosis was higher in fry and fingerlings but low in adults. Also, in white spot disease, the most affected stages as well as the intensity of infestation were recorded the fry and fingerlings. This may be attributed to that the fry and fingerlings skin is easily invaded at this developmental stages. These results were nearly similar with those mentioned by different authors (2, 5, 6).

In the present work it has been shown that the fish which harbored both parasites were suffered from high morbidity and mortalities, which may be due to severe destruction of skin and gills, by the direct action of the parasite and the invasion by secondary pathogenic organisms through destructed skin and or gills.

The clinical signs of infected fish appeared as restless, rubbing bodies against the sides and the immersed objects in the aquarium and swimming near the surface with rapid opercular movement. Heavy and labored breathing, judged by watching the rate of operculum movements, cloudiness, focal redness and lethargy skin were clearly visible.

At advanced stage, fish isolated themselves, sometimes near the water surface. Some fish appeared sluggish, lied on the bottom of the aquarium and finally died. The gross lesions were darkness of the body, turbid thick mucus covering the skin and gills, skin ulcers, fried fins and thickened gill filaments which covered by mucus tinged with blood. In some cases white spots were observed in the gills, skin and fins. These observations were nearly similar with those reported by some investigators (7, 24, 26, 27, 30-32).

Parasitological examination

I. necator was isolated from the skin, gills and fins. The free swimming stages were ovoid to spherical, measured 12-20 x 10.5-18 μ and had two flagellae (Fig. 3.1) of unequal length. The parasitic stage assumed a pyriform shape with pointed anterior end and no flagella and clusters of parasites were sometimes seen on the edges of the gills (Fig. 3.2). Such parasite multiplied by longitudinal binary fission and its pre-division stage was large in size and has more than two flagellae (Fig. 3.3). The nucleus was round to oval; the cytoplasm had basophilic granules and large basophilic body at the base of the flagella. Both parasitic and free swimming stages were

encysted (Fig. 4.1). The parasitic cyst was round to ovoid in shape, it measure 10-15 μ and observed in the skin mucus of moribund and dead fish and in the water sediment of the aquaria. The morphological description of the detected species agreed with that recorded by Van Dujin (23), Urawa and Kusakari (3) and Scheperclaus (31) but our species was larger in size.

In addition presence of *I. necator* cysts on the skin and water sediment is considered as a hazards for the pond as the encysted parasites emerge and attach fish under favorable conditions which plays an important role in spread of the disease during fish transportation.

Ichthyophtherius multifiliis was detected in fresh impression smears from gills, skin and fins. The trophont (fish tissue associated stage) appeared round or oval in shape and uniformly covered by cilia. It measured 90-150 μ m in diameter and possessed a large horseshoe-

shaped macronucleus and a small round micronucleus. The macronucleus appeared bright in color than the cytoplasm as the later contained an enormous number of small food vacuoles (Fig. 3.5). The trophont leaves the host as a mature tomont and secretes gelatinous cyst wall (Fig. 4.2). Within the cyst the tomont begin to divides (Fig. 3.6) to form daughter tomites (Fig. 4.3), which then differentiated into free-swimming theronts. The tomonts were larger than trophont, measured 95 – 200 μ m and were detected in the skin mucus and water sediment. The theront appeared round, covered by cilia, had bean-shaped macronucleus measured 25 – 30 μ m (Fig. 3.4). The description of identified *I. multifiliis* stages agreed with that recorded by Ali (17) and nearly similar with those recorded by different authors (7, 15, 26, 31, 32) but such species was relatively small in size.

Table (2): Prevalence of ichthyobodosis and white spot diseases in fry, fingerlings and adults *O. niloticus* at different seasons.

Season	Ichthyobodosis							White spot disease						
	No of infested fish	Fry		Fingerlings		Adult fish		No of infested fish	Fry		Fingerlings		Adult fish	
		No	%	No	%	No	%		No	%	No	%	No	%
Spring	17	12	70.59	5	29.41	-	-	27	17	63	10	37	-	-
Summer	-	-	-	-	-	-	-	-	-	-	-	-	-	-
Autumn	25	-	-	20	80	5	20	37	-	-	25	67.57	12	32.43
Winter	22	-	-	-	-	22	100	30	-	-	-	-	30	100

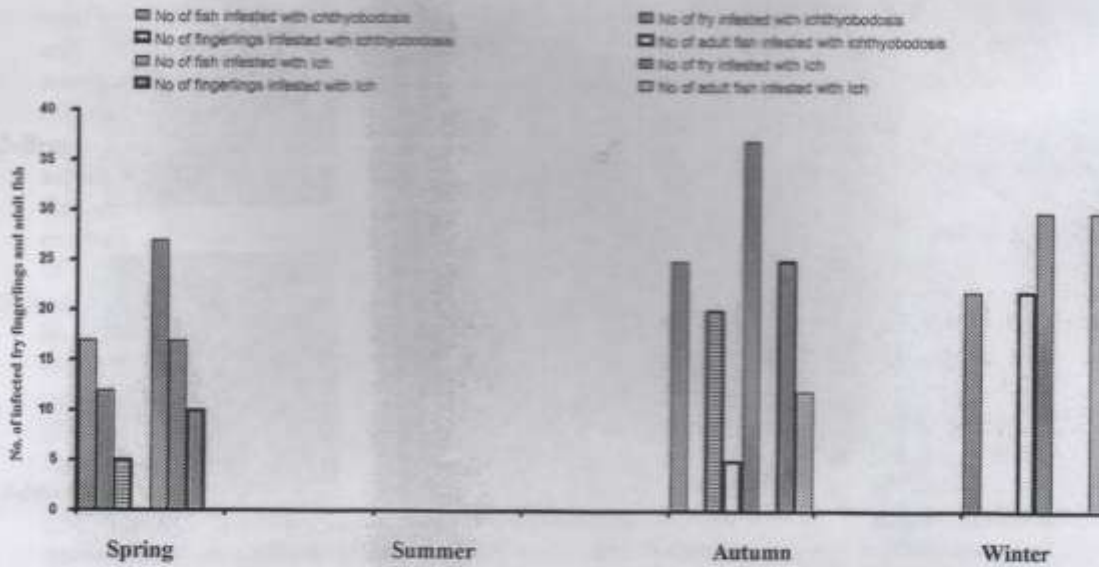


Fig. (2): Prevalence of ichthyobodosis and Ich in fry, fingerlings and adults *O. niloticus* at different seasons.

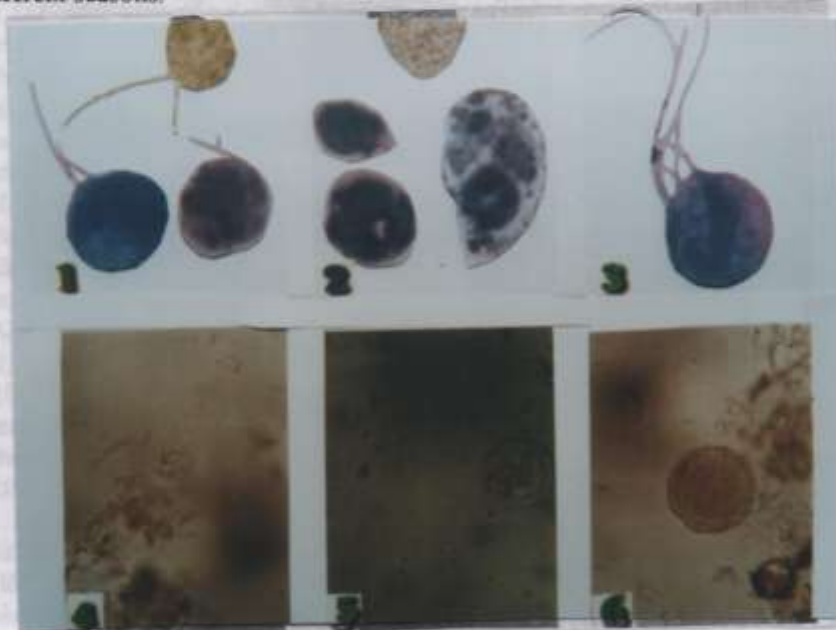


Fig. (3): Wet and /or Gimsa stained preparations. (1) Free living *I. necator*, note the two free flagella (X1000); (2) Parasitic forms of *I. necator*, note the cytostome (arrow) X1000; (3) Free living pre-division form of *I. necator*, note more than two free flagella; (4) Free swimming tomite (infective theront) of *I. multifiliis* (X400); (5) Mature trophont of *I. multifiliis*, note horse shoe-shaped macronucleus (X100); (6) Tomont of *I. multifiliis* showing gelatinous cyst, note start of multiplication (X100).



Fig. (4): Wet mount preparations from sediment. (1) *I. necator* cyst (X1000); (2) *L. multifiliis* tomont showing gelatinous cyst, note a large horse shoe-shaped macromucleus and a small round micronucleus (X100); (3) *L. multifiliis* tomonts, note daughter tomites which differentiate into infective theronts (X100).

REFERENCES

- 1-Becker, C.D. (1977): Flagellate parasites of fish. In: Parasitic Protozoa, Vol. 1, pp. 357-416 Academic Press Inc. London.
- 2-Robertson, D.A. (1979): Host-parasite interactions between *Ichthyobodo necator* (Henneguy, 1883) and Farmed Salmonids. *J. Fish Diseases*, 2: 481-491.
- 3-Urava, S. and Kusakari, M. (1990): The survivability of the ectoparasitic flagellate *Ichthyobodo necator* on Chum salmon fry (*Oncorhynchus keta*) in seawater and comparison to *Ichthyobodo* sp. on Japanese flounder, *Paralichthys Olivaceus* *Journal of Parasitology*, 67: 33-40.
- 4-Bruno, D.W. (1992): *Ichthyobodo* sp. On Farmed Atlantic Salmon, *Salmo salar* L., reared in marine environment. *Journal of Fish Diseases*, 15: 349-351.
- 5-Rosengarten, R. (1985): Parasitological examination of *Salmo gairdneri* on a trout farm in Western Lower Saxony. Inaugural Diss. Tierazliche Hochschule, Hannover, FRG, 125 PP.
- 6-Urava, S. (1987): Effects of environmental stress on the mortality of Chum salmon fry infected with *Ichthyobodo necator*. In: Actual Problems in Fish Parasitology. Hungarian Academy of Sciences, Budapest. p. 99.
- 7-Paperna, I. (1980): Parasites infections and diseases of fish of Africa. Committee for inland fisheries of Africa CIFA Technical papers, 51-62.
- 8-Valtonen, E.T. and Keranen, A. (1981): Ichthyophthiriasis of Atlantic salmon, *Salmo salar*, at the Montta Hatchery in northern Finland in 1978-1979. *Journal of Fish Diseases*, 4: 405-411.
- 9-Hines, R.S. and Spira, D.T. (1974): Ichthyophthiriasis in Mirror carp, *Cyprinus carpio* L. III. Pathology. *Journal of Fish Biology*, 6: 189-196.
- 10-Hoffman, G. (1970): Parasites of North America Freshwater Fishes. University of California Press, Berkeley.
- 11-Nigrelli, R.F., Pokorny, K.S. and Ruggleri, G. D. (1976): Notes on *Ichthyophtherius multifiliis*, a ciliate parasitic on freshwater fishes, with some

- remarks on possible physiological races and species. Transactions of the American Microscopical Society, 95: 607-613.
- 12-Bragg, R.R. (1991): Health status of salmonids in river systems in Natal. I. Collection of fish and parasitological examination. The Onderstepoort Journal of Veterinary Research, 58: 59-62.
- 13-Burkart, M.A., Clark, T.G. and Dickerson, H.W. (1990): Immunization of channel catfish, *Ictalurus punctatus* Rafinesque against *Ichthyophtherius multifiliis* (Fouquet): Killed Versus Live Vaccines, Journal of Fish Diseases, 13: 401-410.
- 14-Moustafa, M. and Easa, M. (1991): The effect of seasonal variations on the development of parasitic gill diseases in Cichlid fish. Benha Vet. Med. J. Vol. 2 (3):
- 15-Abdel-Meguid, M. (1995): Ectoparasite fauna of *G. carp*, *Ctenopharyngodon idella* in Delta breeding station, Egypt Vet. Med.J., Giza, 43 (1): 53-63.
- 16-Paperna, I. (1996): Parasites infections and diseases of fish of Africa CIFA Technical papers, 31-FAO.
- 17-Ali, Y.I. (1998): Studies on some infections in *Mugil cephalus* and *Red tilapia* fries. M.V.Sc. Thesis, Fac. Vet. Med. Cairo Univ. Egypt.
- 18-Maki, J., Brown, C. and Dickerson, W. (2001): Occurrence of *Ichthyophtherius multifiliis* within the peritoneal cavities of infected channel catfish, *Ictalurus punctatus*.
- 19-Brown, E.E. and Gratzek, J.B. (1980): Fish Farming Handbook. Food, Bait, Tropical and Gold fish. AVI Publishing Co., Westport, Connecticut.
- 20-Amlacker, E. (1970): Textbook of Fish Diseases. T.F.S. Publication. New Jersey, U.S.A., p. 117.
- 21-Sanathanand, R. and Srinivasan, A. (1994): A manual of marine zooplankton. Oxford and Ibh publishing Co. PVT. LTD. New Delhi, India, pp. 39-47.
- 22-Lucky, Z. (1977): Methods for the diagnosis of fish diseases. Amerined Publishing Co. New Delhi, Calcutta and New York.
- 23-Van Duijin, C. (1956): Diseases of Fishes. Pub. Water Life, London, 1st Ed. Pp.25-48.
- 24-Gratzek, J.B. (1993): Parasites associated with freshwater tropical fish. In: Fish Medicine (ed. by M. k. Stoskopf) p. 576, Saunders & Co. Philadelphia, PA.
- 25-Woo, P.I.K. (1995): Fish Diseases and Disorders. Vol. 1, Protozoan and Metazoan infection. CAB. International.
- 26-Dickerson, H.W. and Dawe, D.L. (1995): *Ichthyophtherius multifiliis* and *cryptocaryon irritans*. In Fish Diseases and Disorders, Vol. 1 Protozoan and Metazoan infections, C B international pp. 181-227.
- 27-Beck, K., Lewbart, G. and Piner, G. (1996): The occurrence of an Ichthyoboda- Like organism on captive Atlantic spadefish, *Chaetodipterus faber* (Broussonet). J. of FISH diseases, 19: 111- 112.
- 28-Urawa, S., Ueki, N., Nakai, T. and Yamasaki, H. (1991): High mortality of cultured Juvenile Japanese Flounder, *Paralichthys Olivaceus* (Temminck and Schlegel), caused by the parasite flagellate, *Ichthyobodo* sp. Journal of Fish Diseases, 14: 489-494.
- 29-Wahli, T. and Meier, W. (1987): The occurrence and significance of *Ichthyophtherius multifiliis* in switzerland] Vorkommen and Bedeutung Schweizer Archiv Fur Tierheilkunde, 129(4): 205-213.
- 30-Post, G. (1987): Textbook of Fish Health: T.F.H. Publication, Inc. For Revised and Expanded Edition.
- 31-Schaperclaus, W. (1992): Fish Diseases. Vol. 1, 5th Ed., A.A. Balkema/ Rotterdam.
- 32-El-Bahy, N.M. and Gado, M.M. (1999): Immunization trails against *Ichthyophtherius multifiliis* Fouquet (Ciliophora) in Fish. Assiut Vet. Med. J., Vol. 41 (81): 185-199.